

CASE REPORT:

A RARE CASE OF EXTRANODAL NON-HODGKIN'S LYMPHOMA

The complete article is available as a received pdf . The fully formatted published PDF versions are in process.

MAHIMA BHAKAR MOR and RAVI TANDON

Department of Medicine
Institute of Medical Sciences,
Banaras Hindu University,
Varanasi-221005

On December 10, 2010, a 42 yrs old male, resident of eastern Uttar Pradesh, India, presented with complaints of low backache and pain in bilateral lower limbs for last 6 months. Pain was sharp shooting in nature, radiating to posterior aspect of thigh, increased with coughing and sneezing, suggestive of a radicular origin. This was followed by insidious onset, slowly progressive motor weakness and wasting of muscles in bilateral lower limbs for last one month. Patient also had retention of urine and faeces for past 3 days.

There was no H/O band-like sensation or trauma to spine or upper limb involvement or cranial n involvement or fever or loss of appetite or decreasing body wt.

Patient was habituated to tobacco chewing and consumes alcohol occasionally.

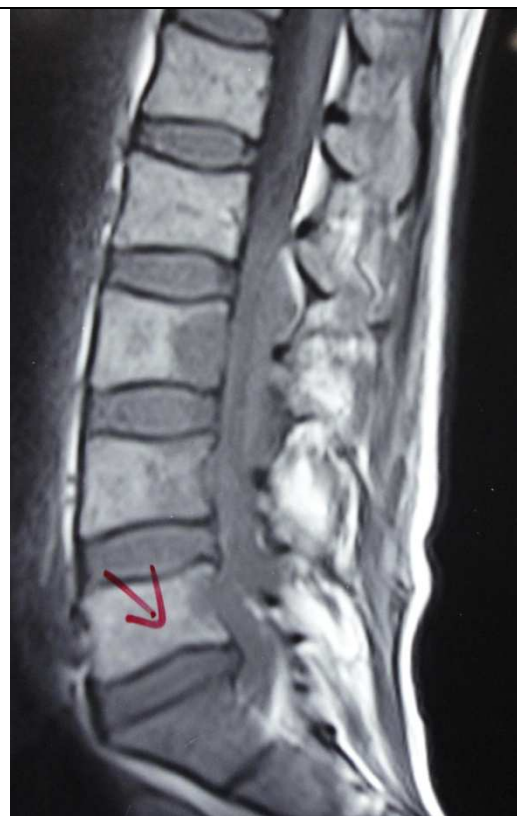On general examination, his vitals were stable. There was no pallor or lymphadenopathy or spinal deformity or any other significant finding.

On CNS examination; upper limbs, cranial nerves and higher mental functions were normal. Findings were confined to lower limbs. Bulk, tone and power were reduced at all muscles around knee joint and ankle joint. Around hip joint, flexors were spared and extensors and abductors were weak. Patient was bed-ridden and could not stand and walk. Sensory examination revealed impairment in all modalities (pain, touch, temp, position) below L2 dermatome.

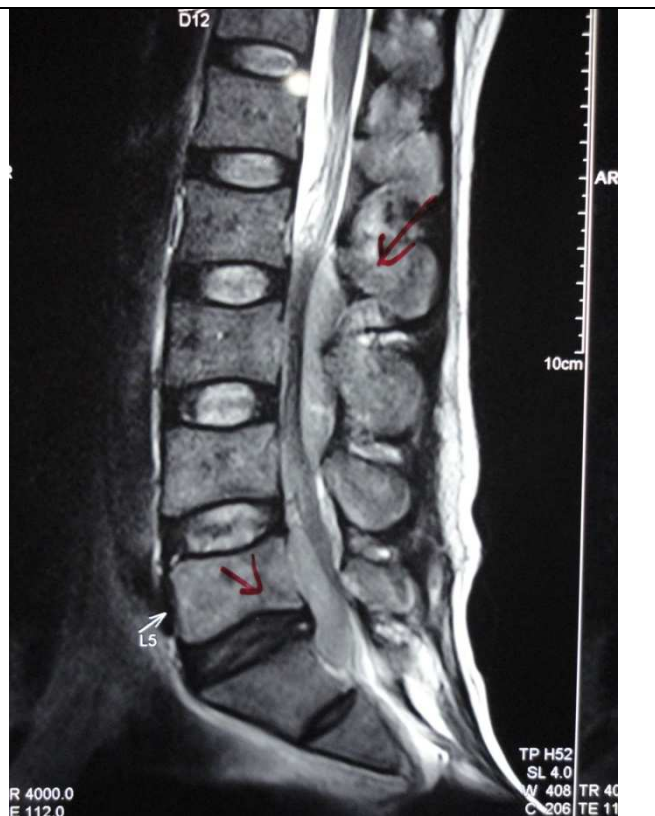B/L fundus was normal. Other system examination was normal.

An anatomical diagnosis of Cauda Equina syndrome was kept.

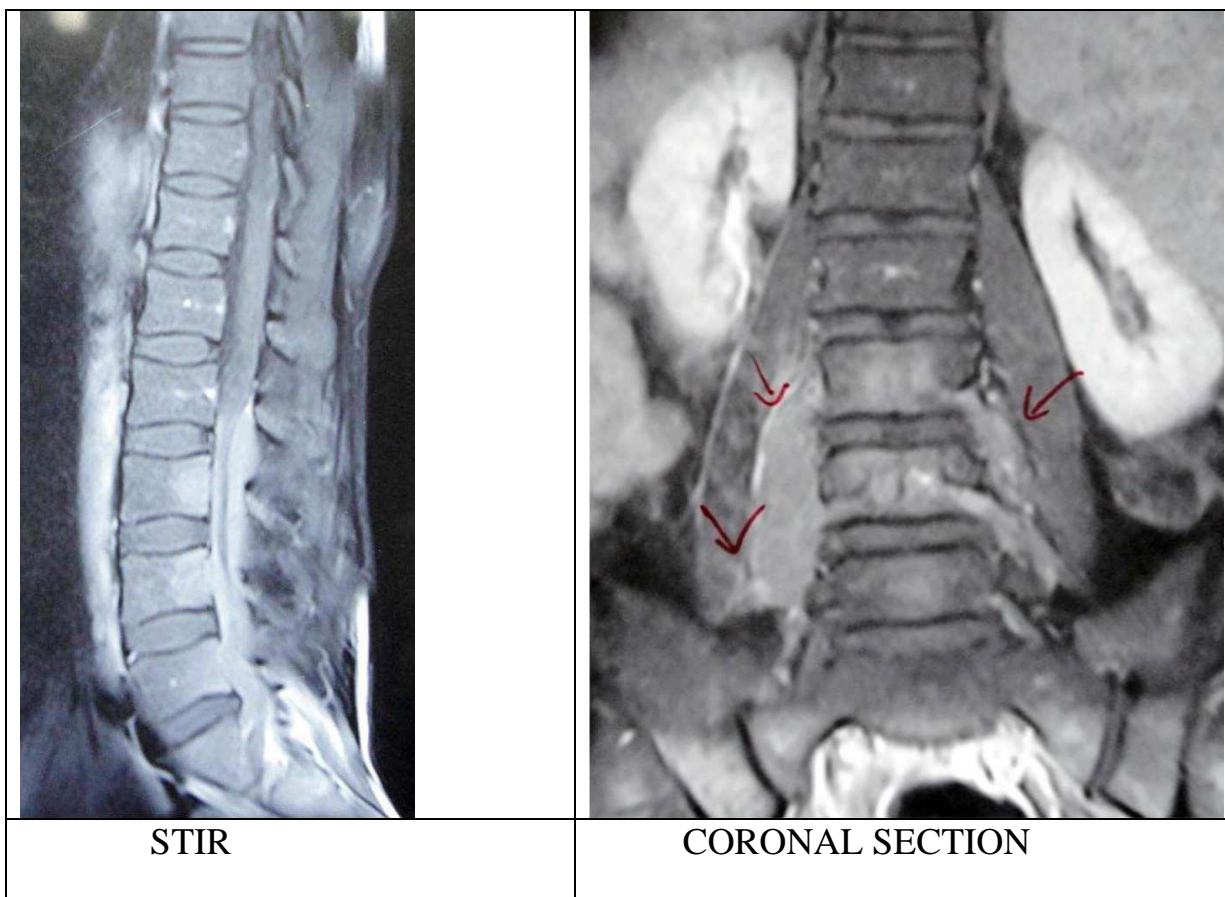
Imaging of the LS spine revealed altered marrow signal intensity over L3-5 vertebrae with soft tissue component in epidural space with paravertebral extension leading to compression over nerve roots. This was hypointense in T1 and hyperintense in T2 images. Post-contrast enhancement was seen.



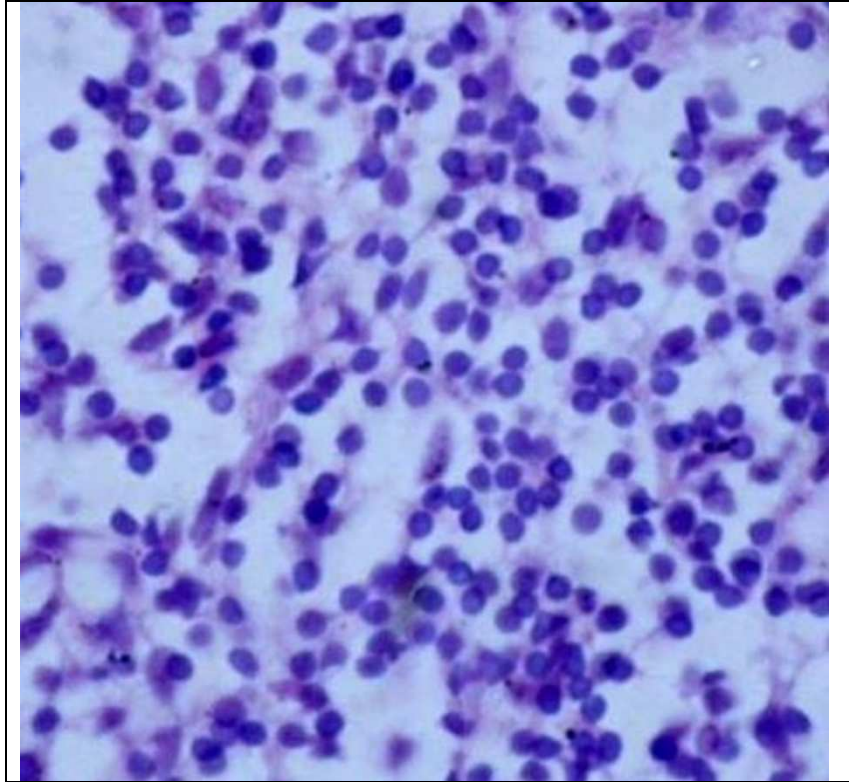
T 1 IMAGE



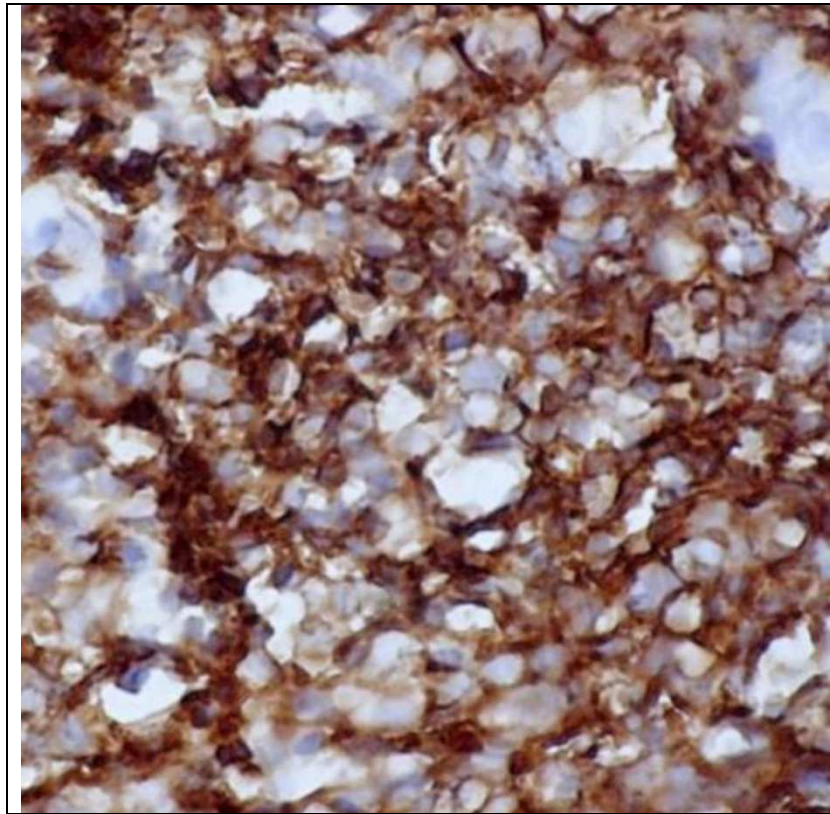
T 2 IMAGE



CT-guided biopsy of the mass revealed monomorphic population of small lymphocytic lymphoblasts with hyperchromatic nucleus, without discernible nucleoli, with scanty cytoplasm, suggestive of Intermediate grade Non Hodgkin's Lymphoma.



Biopsy tissue was then subjected to IHC which revealed CD 20 marker as strongly positive with slight positivity of CD 3 marker.



As a part of staging, GBP, BMA, USG-abdomen and scrotum, MRI-brain, CT-chest, abdomen, pelvis, UGI AND LGI endoscopy, ENT examination, myeloma profile, serum PSA were done. Surprisingly all reports came out to be normal.

Final diagnosis of Primary Bone Non Hodgkin Lymphoma-B cell type, stage 1EA was made and treated accordingly.

Treatment plan-6 cycles of CHOP regime followed by RT (40 Gy in 20 fractions over 4 weeks). Till date 2 cycles of CT have been given. Patient has shown remarkable clinical improvement. He can now walk without support and has no bladder-bowel complaints.

DISCUSSION-

Primary Bone Lymphoma is a rare clinicopathological entity that accounts for 3% of all Lymphomas, 5% of all extranodal Lymphomas, 2% of all primary Non-Hodgkins Lymphomas and 7% of all malignant bone tumors (1, 2). It occurs more commonly in 5-6 th decade of life and appendicular skeleton is more commonly involved than axial skeleton. Primary vertebral location account for only 1.7% of all Primary Bone Lymphomas (3).Non Hodgkins Lymphoma outweighs Hodgkin Lymphoma. B cell type is more common than T

cell type. Primary Non Hodgkin's Lymphoma of bone usually presents as osteolytic lesion on plain X-ray (4). Chemoradiation is the most effective therapy (5). Overall prognosis is favourable (Overall Survival >60%) (6).

The case further suggests that a possibility of bone lymphoma should always be kept in mind while evaluating the patients with cord or nerve root involvement, especially in the elderly age group with cauda equina syndrome. Accurate staging is essential as demarcation between stage 1 and stage 4 is marginal. Appropriate identification allows for appropriate treatment.

REFERENCES:

- 1.) Baar J, Burkes RL, Gospodarowicz M. Primary non-Hodgkin's lymphoma of bone. *Semin Oncol.* Jun 1999; 26(3):270-5.
- 2.) Isaacson P, Norton A. Extranodal lymphoma in miscellaneous sites. In: Isaacson P, Norton A eds. *Extranodal Lymphomas*, New York: Churchill Livingstone 1994; pp 289-98.
- 3.) Rathmell AJ, Gospodarowicz MK, Sutcliffe SB, Clark RM. Localized extradural lymphoma: survival, relapse pattern and functional outcome. The Princess Margaret Hospital Lymphoma Group. *Radiother Oncol.* 1992; 24(1):14–20. doi: 10.1016/0167-8140(92)90348-X.
- 4.) Mulligan ME, McRae GA, Murphey MD. Imaging features of primary lymphoma of bone. *AJR Am J Roentgenol.* Dec 1999; 173(6):1691-7
- 5.) Beal K, Allen L, Yahalom J. Primary bone lymphoma: treatment results and prognostic factors with long-term follow-up of 82 patients. *Cancer* 2006; 106:2652-6
- 6.) de Camargo OP, dos Santos Machado TM, Croci AT, et al. Primary bone lymphoma in 24 patients treated between 1955 and 1999. *Clin Orthop Relat Res.* Apr 2002 ; (397):271-80.